

**Study of Combination Regimens of Anti-Amoebic  
Drugs for the Treatment of Amoebic Dysentery Caused  
by *E. histolytica***

**A Dissertation submitted to the Department of Pharmacy, East West  
University, as the partial fulfillment of the requirements for the degree of  
Master of Pharmacy.**



**Supervised by**

Dr. Sufia Islam  
Associate Professor  
Department of Pharmacy  
East West University

**Submitted by**

Shanjida Zarin Suki

ID: 2014-3-79-015

Fall: 2015

**Department of Pharmacy  
East West University**

This thesis paper  
is dedicated  
to my beloved Parents...

---

## DECLARATION BY THE CANDIDATE

I, Shanjida Zarin Suki (ID: 2014-3-79-015), hereby declare that this dissertation entitled “Study of Combination Regimens of Anti-Amoebic Drugs for the Treatment of Amoebic Dysentery Caused by *E. histolytica*” submitted to the Department of Pharmacy, East West University, as the partial fulfillment of the requirement for the degree of Master of Pharmacy, is a genuine & authentic research work carried out by me under the guidance and supervision of Dr. Sufia Islam, Associate Professor, Department of Pharmacy, East West University, Dhaka. The contents of this dissertation, in full or in parts, have not been submitted to any other Institute or University for the award of any Degree or Diploma of Fellowship.

-----  
Shanjida Zarin Suki  
ID: 2014-3-79-015  
Department of Pharmacy  
East West University  
Jahurul Islam city, Aftabnagar, Dhaka

## CERTIFICATION BY THE SUPERVISOR

This is to certify that the dissertation, entitled “Study of Combination Regimens of Anti-amoebic Drugs for the Treatment of Amoebic Dysentery Caused by *E. histolytica*” is a beneficial research work done under my guidance and supervision by Shanjida Zarin Suki (ID: 2014-3-79-015), as the partial fulfillment of the requirement for the degree of Master of Pharmacy.

-----  
Dr. Sufia Islam  
Associate Professor  
Department of Pharmacy  
East West University  
Jahurul Islam city, Aftabnagar, Dhaka

## ENDORSEMENT BY THE CHAIRPERSON

This is to certify that the dissertation, entitled “Study of Combination Regimens of Anti-Amoebic Drugs for the Treatment of Amoebic Dysentery Caused by *E. histolytica*” is a bonafide research work done by Shanjida Zarin Suki (ID: 2014-3-79-015) as partial fulfillment of the requirements for the degree of Master of Pharmacy.

-----  
Dr. Shamsun Nahar Khan  
Chairperson and Associate Professor  
Department of Pharmacy  
East West University  
Jahurul Islam city, Aftabnagar, Dhaka

## ACKNOWLEDGEMENTS

All praise is for Almighty Allah for all the bounties granted to me and only with His guidance and help this achievement has become possible.

It's my pleasure to express heartiest regards and gratitude to my respected teacher and supervisor **Dr. Sufia Islam**, Associate Professor, Department of Pharmacy, East West University, for her expert supervision, constructive criticism, valuable advice, optimistic counseling, constant support and continuous backup and encouragement throughout every phase of the project as well as to prepare this dissertation.

I would also like to put forward my most sincere regards and profound gratitude to **Dr. Shamsun Nahar Khan**, Chairperson & Associate Professor, Department of Pharmacy, East West University, for giving me the opportunity to conduct such an interesting research and for facilitating a smooth conduction of my study.

I am grateful to **Md. Abdullah Siddique**, research officer of the department of Parasitology laboratory for his support in my study at International Centre for Diarrheal Disease Research, Bangladesh (icddr'b).

I would also like to extend my thanks to **Mr. Tirtha Nandi**, lecturer, Department of Pharmacy, East West University, **Mr. Ajoy Roy**, senior lab officer, Department of Pharmacy, East West University, all the research students in the lab and other staffs of the Department of Pharmacy for their help and assistance, friendly behavior and earnest co-operation which enabled me to work in a very congenial and comfortable ambience.

I owe special thanks to my fellow research group member **Rajashree Chowdhury** for her immense support and contribution in my research work.

Last but not the least, I would like to thank my family, and friends for their care and encouragement during my research work.

## CONTENTS

SL No.	Name of the Topics	Page No.
<b>Chapter One: Introduction</b>		
1.1	Background Information	01
1.2	Amoebiasis	01
1.3	Species of <i>Entamoeba</i>	02
1.4	Amoeba	02
1.5	Distribution	04
1.6	Life cycle	05
1.7	<i>Entamoeba histolytica</i>	06
1.8	Scientific classification	06
1.9	Geographical distribution	06
1.10	Life cycle	06
1.11	Mode of infection	09
1.12	Excystation	10
1.13	Pathology	10
1.14	Clinical Manifestations	13
1.15	Structure	16
1.16	Transmission	16
1.17	Genomic Diversity of Amoebiasis	17
1.18	Pathophysiology	17
1.19	Etiology	20
1.20	Treatment	21
1.21	Metronidazole	22
1.22	Ornidazole	26
1.23	Tinidazole	27
1.24	Secnidazole	28
1.25	Objectives	31
1.26	Aim of the study	31

<b>Chapter Two: Material And Method</b>		
2.1	Collection of sample	32
2.2	Preparation of antimicrobial agents	32
2.3	Clinical isolates	32
2.4	The instruments	32
2.5	In vitro drug sensitivity assay	37
<b>Chapter Three: Result and Discussion</b>		
3.1	Viable count of clinically isolates <i>E. histolytica</i> from Metronidazole, Ornidazole and their Combination after 4 hours of incubation	39
3.2	Viable count of clinically isolates <i>E. histolytica</i> from Metronidazole, Tinidazole and their Combination after 4 hours of incubation	40
3.3	Viable count of clinically isolates <i>E. histolytica</i> from Metronidazole, Secnidazole and their Combination after 4 hours of incubation	41
3.4	Discussion	43
3.5	Conclusion	45
<b>References</b>		46



## LIST OF FIGURES

Figure No.	Name of the Figure	Page No.
1.1	Amoeba proteus	03
1.2	Life cycle of <i>E. histolytica</i>	07
1.3	Stages of life cycle of <i>E. histolytica</i>	08
1.4	Amebas found in stool specimens of humans	12
1.5	Pathogenesis of <i>E histolytica</i> infection	13
1.6	Multiplication and life cycle of <i>E histolytica</i>	14
1.7	<i>Entamoeba histolytica</i> cyst	18
1.8	<i>Entamoeba histolytica</i> trophozoite	18
2.1	Micropipette	33
2.2	Analytical balance	33
2.3	Microtips holder	34
2.4	Microtiter plate	34
2.5	Laminar flow	35
2.6	Microscope	35
2.7	Incubator	36
2.8	Haemocytometer	36
2.9	Autoclave	37
3.1	Viable count of <i>E. histolytica</i> from Metronidazol, Ornidazol and their combination after 04 hours incubation	40

3.2	Viable count of <i>E. histolytica</i> from Metronidazole, Tinidazole and their combination after 04 hours incubation	41
3.3	Viable count of <i>E. histolytica</i> from Metronidazole, Secnidazole and their combination after 04 hours incubation	42

## LIST OF TABLES

Table No.	Name of the Table	Page No.
1.1	Classification of Amebiasis	14
3.1	Viable count of <i>E. histolytica</i> in Metronidazole, Ornidazole and their Combination after 4 hours of incubation	39
3.2	Viable count of <i>E. histolytica</i> in Metronidazole, Tinidazole and their Combination after 4 hours of incubation	40
3.3	Viable count of <i>E. histolytica</i> in Metronidazole, Secnidazole and their Combination after 4 hours of incubation	42

## Abstract

*Entamoeba histolytica* is the etiological agent of amoebic dysentery and amoebic liver abscess. Amoebiasis is one of the most common health problems in the developing countries. Almost 50 million people each year are infected by Amoebiasis. Poverty, ignorance, overcrowding, poor sanitation and malnutrition favor transmission and increase disease burden. The objective of the study is to determine the sensitivity of the combination regimens of anti-amoebic drugs against clinical isolates of *E. histolytica*. The clinical isolates of *E. histolytica* were treated with metronidazole, ornidazole, metronidazole+ornidazole, secnidazole, metronidazole + secnidazole, tinidazole, and metronidazole+tinidazole at different concentrations (12, 6, 3 & 1.5 mg/ml). Drug sensitivity assay of the samples was carried out by using microtiter plates containing 50 µl of parasite suspension ( $3 \times 10^6$  parasites/ml). Plates were incubated at 37°C. After 4 hours the viable parasites were counted by haemocytometer under microscope. Viable counts of the *E. histolytica* in each concentration of drugs were compared to the control. Result showed that combination of metronidazole and ornidazole (1.5 mg/ml) inhibit the growth of *E. histolytica* and it has found significantly different when compared with the control ( $p < 0.05$ ). Combination of tinidazole and metronidazole at the concentration of 6 and 12mg/ml has also found statistically significant ( $p < 0.05$ ) to inhibit the growth of *E. histolytica* when compared with the control. At the concentration of 3 mg/ml, only tinidazole was significantly different when compared with the control to inhibit the growth of *E. histolytica*. We conclude that treatment with combination drugs may be a useful alternative to inhibit the growth of *E. histolytica*. Prior to the clinical study, further study is needed to explore different combinations of drugs at different concentrations and time intervals to determine the *in vitro* sensitivity against *E. histolytica* isolates.

# Chapter One: Introduction

## 1.1 Background Information

Amoebiasis is a gastrointestinal infection caused by *Entamoeba histolytica*. It is present all over the world (Beeching and Gill, 2014). *E. histolytica* infection remains a major cause of morbidity and mortality worldwide (Nair and Variyam, 2014). On a global basis, amoebiasis affects approximately 50 million persons each year resulting in 100,000 deaths (Petri, 2003). Amoebiasis is also very common in Bangladesh (Hoque, 2014).

*E. histolytica* was first identified by Hippocrates around 300 B.C. by describing a patient with dysentery and fever. Developments came later in 1855 when it was suggested that the disease might have a parasitic origin. Finally, *E. histolytica* was identified from a stool sample in 1875 by Fedor Losch (also known as Fedor Lesh). Throughout the world, amoebiasis is the second leading cause of death from a parasitic disease. Although it is the second leading cause of death from parasitic diseases, about 90% of the people exposed to *E. histolytica* are asymptomatic or report very mild symptoms (Petri and Tanyuskel, 2003).

## 1.2 Amoebiasis

Amoebiasis, also known as amebiasis or entamoebiasis, is an infection caused by any of the amoebas of the *Entamoeba* group. Symptoms are most common upon infection by *Entamoeba histolytica*. Amoebiasis can present with no, mild, or severe symptoms. Symptoms may include abdominal pain, mild diarrhoea, bloody diarrhea or severe colitis with tissue death and perforation. This last complication may cause peritonitis. People affected may develop anemia due to loss of blood.

Invasion of the intestinal lining causes amoebic bloody diarrhea or amoebic colitis. If the parasite reaches the bloodstream it can spread through the body, most frequently ending up in the liver where it causes amoebic liver abscesses.

Liver abscesses can occur without previous diarrhea. Cysts of *Entamoeba* can survive for up to a month in soil or for up to 45 minutes under fingernails.

It is important to differentiate between amoebiasis and bacterial colitis. The preferred diagnostic method of it is through faecal examination under microscope, but requires a skilled microscopist and may not be reliable when excluding infection. Increased white blood cell count is present in severe cases, but not in mild ones. The most accurate test is for antibodies in the blood, but it may remain positive following treatment (Farrar et al., 2013).

### **1.3 Species of Entamoeba**


The genus *Entamoeba* contains many species, six of which (*Entamoeba histolytica*, *Entamoeba dispar*, *Entamoeba moshkovskii*, *Entamoeba polecki*, *Entamoeba coli*, and *Entamoeba hartmanni*) reside in the human intestinal lumen. *Entamoeba histolytica* is the causative agent of amebiasis and is considered a leading parasitic cause of death worldwide in humans. Although recent studies highlight the recovery of *E. dispar* and *E. moshkovskii* from patients with gastrointestinal symptoms, there is still no convincing evidence of a causal link between the presence of these two species and the symptoms of the host (Fotedaret al., 2007). New approaches to the identification of *E. histolytica* are based on detection of *E. histolytica*-specific antigen and DNA in stool and other clinical samples. Several molecular diagnostic tests, including conventional and real-time PCR, have been developed for the detection and differentiation of *E. histolytica*, *E. dispar*, and *E. moshkovskii* in clinical samples (Fotedaret al., 2007).

### **1.4 Amoeba**

An amoeba is any of several tiny, one-celled protozoa in the phylum (or primary division of the animal kingdom) Sarcodina. Amoebas live in freshwater and salt water, in soil, and as parasites in moist body parts of animals. They are composed of cytoplasm (cellular fluid) divided into two parts: a thin, clear, gel-like outer layer that acts as a membrane (ectoplasm); and an inner, more watery grainy mass (endoplasm) containing structures called organelles. Amoebas may have one or more nuclei, depending upon the species. The word amoeba comes

from a Greek word meaning "to change." The amoeba moves by continually changing its body shape, forming extensions called pseudopods (false feet) into which its body then flows. The pseudopods also are used to surround and capture food—mainly bacteria, algae, and other protozoa—from the surrounding water. An opening in the membrane allows the food particles, along with drops of water, to enter the cell, where they are enclosed in bubble like chambers called food vacuoles. There the food is digested by enzymes and absorbed into the cell. The food vacuoles then disappear. Liquid wastes are expelled through the membrane (UXL Encyclopedia of Science, 2002).

Water from the surrounding environment flows through the amoeba's ectoplasm by a process called osmosis. When too much water accumulates in the cell, the excess is enclosed in a structure called a contractile vacuole and squirted back out through the cell membrane. The membrane also allows oxygen to pass into the cell and carbon dioxide to pass out. The amoeba usually reproduces asexually by a process called binary fission (splitting in two), in which the cytoplasm simply pinches in half and pulls apart to form two identical organisms (daughter cells). This occurs after the parent amoeba's genetic (hereditary) material, contained in the nucleus, is replicated and the nucleus divides (a process known as mitosis). Thus, the hereditary material is identical in the two daughter cells (UXL Encyclopedia of Science, 2002).



**Figure 1.1:** *Amoeba proteus*.

If an amoeba is cut in two, the half that contains the nucleus can survive and form new cytoplasm. The half without a nucleus soon dies. This demonstrates

the importance of the nucleus in reproduction. Some amoebas protect their bodies by covering themselves with sand grains. Others secrete a hardened shell that forms around them that has a mouth-like opening through which they extend their pseudopods. Certain relatives of the amoeba have whip like organs of locomotion called flagella instead of pseudopods. When water or food is scarce, some amoebas respond by rolling into a ball and secreting a protective body covering called a cyst membrane. They exist in cyst form until conditions are more favorable for survival outside (UXL Encyclopedia of Science, 2002).

There are many varieties of free-living amoeba, but only four genera have been causally associated with disease in humans. (Trabelsi et al., 2012). These are *Acanthamoebas* pp., *Balamuthia mandrillaris* (the only known species of *Balamuthia*), *Naegleria fowleri* (sometimes considered not to be an amoeba at all, but more closely related to *Leishmania* and *Trypanosoma*) and *Sappinia pedata*. They are distinct from the more famous *Entamoeba histolytica* (an obligate anaerobic parasite which can cause amoebiasis, amoebic dysentery and amoebic liver abscesses). *Acanthamoebas* pp. and *B. mandrillaris* are opportunistic pathogens causing infections of the CNS, lungs, sinuses and skin, mostly in immunocompromised humans. *B. mandrillaris* is also associated with disease in immunocompetent children, and *Acanthamoebas* pp. cause a sight-threatening keratitis, mostly in contact lens wearers. *N. fowleri* causes an acute and fulminating meningoencephalitis in immunocompetent children and young adults. A few human cases of encephalitis caused by *Sappinia diploidea* have been described (Visvesvara et al., 2007; Visvesvara et al., 2011; Qvarnstrom et al., 2009).

Free-living amoebae cause rare but devastating disease. They are aerobic (other species of amoeba are anaerobic). They have also been called amphizoic amoebae, as they are able to exist as free-living organisms in nature and only occasionally invade a host and live as parasites within host tissue (Gurvinder, 2014).

## 1.5 Distribution



These organisms are ubiquitous and found worldwide. *Acanthamoebas* pp. are found in soil, dust, air and water (eg, swimming pool, domestic and sewage), ventilation and air conditioning systems. They have been isolated in hospitals, medicinal pools, dental treatment units, dialysis machines and contact lenses. They have also been found in mammalian cell cultures, human nostrils and throats and human and animal brain, skin, and lung tissues. In cell cultures they are commonly contaminants. This is how they were discovered in the 1950s - they grew on cell cultures grown for the polio vaccine. *Acanthamoebas* pp. can also be found in fish and have been isolated from the nasal and throat mucosa of healthy humans (Gurvinder, 2014).

*B. mandrillaris* has not been isolated from the environment but has been isolated from autopsy specimens of infected humans and animals. *N. fowleri* is also ubiquitous and found in soil and warm fresh water. *Sappinias* pp. is found in soil and tree bark. Both *Acanthamoebas* pp. and *B. mandrillaris* can act as hosts for other bacterial infections - eg, legionellosis (Gurvinder, 2014).

## 1.6 Life cycle

There are two stages in the life cycle of *Acanthamoeba*, *Balamuthia* and *Sappinias* species:

### - Active feeding stage

During this stage the trophozoites are actively dividing by feeding on bacteria, yeast and algae or axenically.

### - Dormant cyst stage

Cysts form once there is a change in the environment of the trophozoites - eg, nutrient deprivation or changes in temperature. The cysts are resistant to chlorination and antibiotics.

There are four stages in the lifecycle of *N. fowleri*:

The trophozoites are 10-15 µm in diameter.

They produce broadly rounded lobopodia.

Cysts are single-walled, spherical and 8-12 µm in diameter.

The trophozoites can also transform to a flagellated form (Gurvinder, 2014).

### **1.7 *Entamoeba histolytica***

*Entamoeba histolytica* is an anaerobic parasitic protozoan, part of the genus *Entamoeba*. Mammals such as dogs and cats can become infected transiently, but are not thought to contribute significantly to transmission (Ryan & Ray, 2004). *E. histolytica* commonly contracted by ingesting contaminated water or food. The parasite has a two-stage life cycle in which the infective stage in the environment is the cyst and the motile stage within the host is the trophozoite (Weedall and Hall, 2011).

### **1.8 Scientific classification**

Kingdom: Amoebozoa

Phylum: Archamoebae

Subphylum: Conosa

Class: Tubulinea

Genus: *Entamoeba*

Species: *E. histolytica*

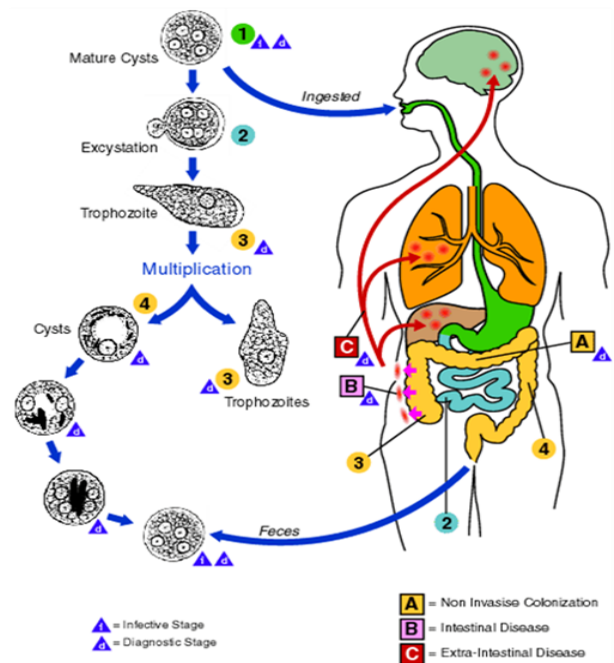
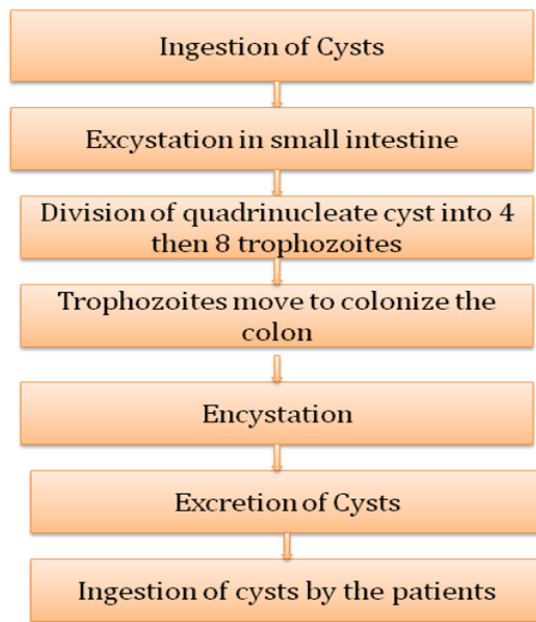### **1.9 Geographical distribution:**

*E. histolytica* is cosmopolitan in distribution, but is more common in tropical and sub-tropical countries. In India it occasionally takes an epidemic form. It is estimated that about seven to eleven per cent of the population in India suffers from its infection ( Saritha, 2015).

### **1.10 Life cycle**

*E. histolytica* is a monogenetic parasite as its life cycle is completed in a single host i.e., man. Three distinct morphological forms exist in its life cycle.

-Trophozoite, Pre-cystic stage and Cystic stage.

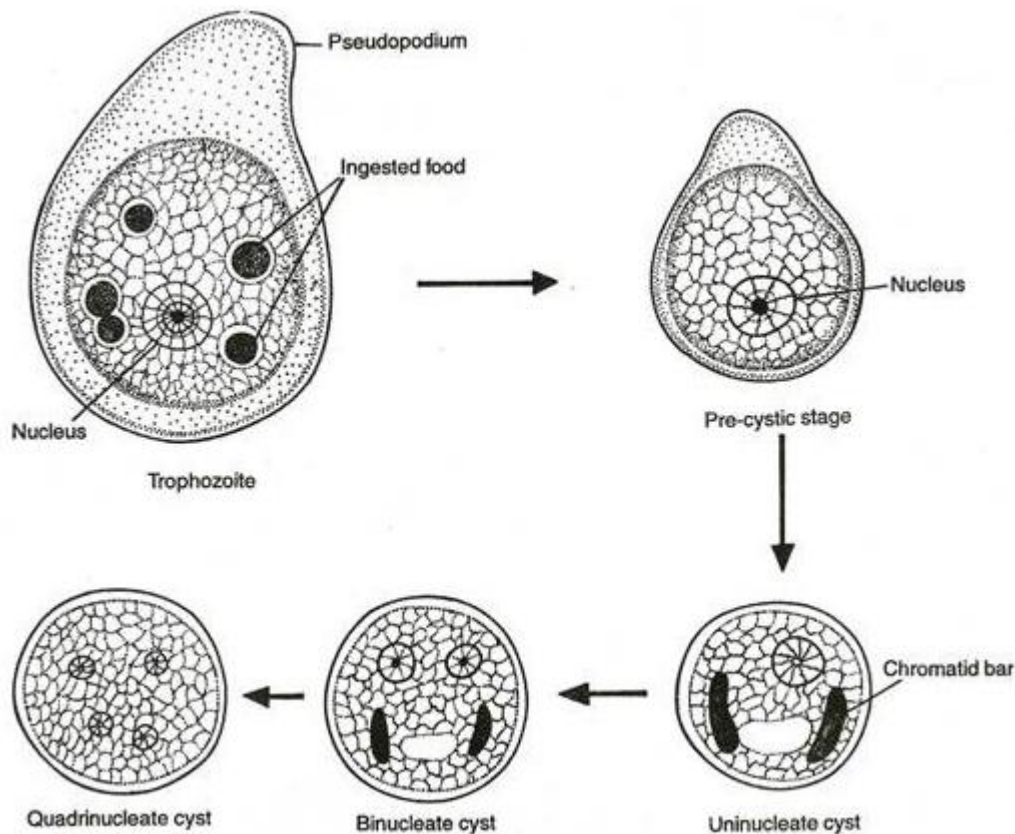


**Figure 1.2: Life cycle of *E. histolytica***

## Trophozoite

It is the growing or feeding stage of the parasite. During this stage the parasite resides in the mucosa and sub-mucosa layers of the large intestine of man. Trophozoites are unicellular organisms, with a size ranging from 18 to 40  $\mu\text{m}$  in diameter (average being 20 to 30  $\mu\text{m}$ ). During the optimal living condition the parasites exhibit slow gliding movement by forming pseudopodia, hence the body shape is not fixed because of constantly changing position (Saritha, 2015).

The cytoplasm inside the body of trophozoite is divisible into clear, transparent ectoplasm and inner granular endoplasm. The endoplasm contains nucleus, ingested red blood cells and tissue debris. A single spherical nucleus lies inside the endoplasm. The size of the nucleus ranges from 4 to 6  $\mu\text{m}$ . Nucleus contains a central dot like Karyosome and a delicate single layered nuclear membrane containing fine chromatin granules. The space between Karyosome and the nuclear membrane is traversed by radially arranged fine threads of limn network (Saritha, 2015).



**Figure 1.3: Stages of life cycle of *E. histolytica***

Trophozoite secretes a proteolytic ferment around itself. This ferment is of the nature of histolysin which brings about destruction and necrosis of the surrounding host tissues to be absorbed later by the parasite as food. Trophozoite reproduces by binary fission and increases their number. They are exclusively parasitic in nature, growing at the expense of living tissues and multiplying rapidly to maintain their presence in good number (Saritha, 2015).

**Pre- Cystic stage:**

It is an intermediate stage between the trophozoite and cystic forms. During this stage the parasite reduces in size (10 – 20  $\mu\text{m}$ ), becomes avoid in shape and bears a single blunt pseudopodia. The endoplasm does not contain ingested R.B.C's and other tissue debris, indicating that during this stage the parasite stop feeding. A single nucleus remains present.

**Cystic stage:**

Cyst formation occurs inside the lumen of the host's intestine. The precystic parasite moves into the gut lumen to be transformed into cystic form, a process

called “encystations”. During the process of encystations, the parasite becomes round and get surrounded by a double refractile wall, called the cyst wall. A cyst in the beginning is uninucleate body with size ranging from 7–15  $\mu\text{m}$ , in different races. The nucleus inside the cyst soon divides by binary fission to become a binucleate form and then to quadrinucleate form. In this way, a single nucleus by mitotic division forms four daughter nuclei, undergoes reduction in size and ultimately becomes 2  $\mu\text{m}$  in diameter. Inside the cytoplasm of the cyst develops certain extra nuclear bodies like chromatid bars and glycogen mass. Chromatid bars or chromatoids are dark oblong bar like structures varying in size and number (1 to 4). In addition to chromatid bars the cyst also contains mass of glycogen in the form of brown vacuolar structure (Saritha, 2015).

As the cyst transform from uninucleate to quadrinucleate stage, both chromatid bars and glycogen vacuole reduces in size and finally disappear. The whole process of encystation occurs within a few hours. The life of a matured cyst (quadrinucleate form) inside the lumen of the host’s gut is only two days. The mature quadrinucleate cysts pass out of their host’s body through faeces. Outside the body of the host, the cyst survives for ten days and their thermal death point is about 50°C (Saritha, 2015).

### **1.11 Mode of infection**

A matured quadrinucleate cyst of *E.histolytica* is the infective stage of the parasite. Transmission of *E. histolytica* from one person to another occurs due to ingestion of these cysts. Fecal contamination of edible substances and drinking water are the primary cause of infection. Following are the mode of transmission of this parasite.

#### **(a) Fecal-oral route:**

In majority of cases infection takes place through intake of contaminated uncooked vegetables and fruits. Insect vectors like flies, cockroaches and rodents act as agent to carry infective cysts to the food and drink. Sometimes drinking

water supply contaminated with infected faeces give rise to epidemics (Saritha, 2015).

**(b) Oral-rectal contact:**

Sexual transmission by oral-rectal contact is also one of the modes of transmission, especially among male homosexuals (Saritha, 2015).

### **1.12 Excystation**

When the quadrinucleate cyst enters in the ileum of the small intestine of the new host, the process of excystation begins. Excystation is the process of transformation of cysts to the trophozoites. It occurs in the intestinal lumen of the host. The cyst wall gets dissolved by the neutral or alkaline intestinal juice. The nucleus inside the cyst divides once again to form eight daughter nuclei. Certain amount of cytoplasm surrounds each of the nuclei to form 8 trophozoites. The parasite at this stage moves into the caecum of the host's large intestine, gets attached to the epithelial cells of the large intestine, produces necrosis by proteolytic ferment (cytolysin) and enters into the mucosa and sub-mucosa layers by means of their own mobility action (Saritha, 2015).

### **1.13 Pathology**

The incubation period in man varies a great deal depending upon the host's resistance to the parasite. Generally it is four to five days i.e., the symptoms of the disease appear 4 to 5 days after the host being infected with the parasite. The pathological conditions arising out of the infection of *E. histolytica* is as "amoebiasis". Amebiasis is an infectious disease caused by a parasitic one-celled microorganism (protozoan) called *Entamoeba histolytica*. Persons with amoebiasis may experience a wide range of symptoms, including diarrhea, fever, and cramps. The disease may also affect the intestines, liver, or other parts of the body (Gale Encyclopedia of Medicine, 2008). The symptoms of the disease however, appear in only 10 per cent of the infected individuals.

The pathology can be broadly divided into two parts:

1. Intestinal or Primary lesions
2. Metastatic or Secondary lesions.

## **Primary or intestinal lesions**

Primary infection of this parasite is limited entirely to the large intestine. The trophozoites after entering the mucosa and sub-mucosa layers of the large intestine multiply in number and feed upon the intestinal tissues by destroying them through the proteolytic ferment secreted by them. The different pathological conditions arising out due to the presence of *E. histolytica* in the large intestine are-

### **- Amoebic dysentery:**

The presence and activity of the parasite in the wall of large intestine causes amoebic dysentery characterised by frequent passage of stool and griping pain. This contains mucus and occasionally blood.

### **- Amoebic ulcers:**

In addition to amoebic dysentery, the presence of the parasite causes multiple ulcers in the caecum, ascending colon and rectum. In advanced cases, the ulcers may be large and may also show haemorrhage due to erosion of blood vessels.

In acute case of parasite infection perforation and gangrene of intestinal wall may occur. Pericolonic abscesses & peritonitis have also been reported (Saritha, 2015).

## **Metastatic or secondary lesions:**

In chronic cases the parasite may enter into the blood circulation and reaches the different parts of the body to cause extra intestinal or metastatic lesion. It is also known as "tissue amoebiasis". The commonest form of tissue amoebiasis are-

### **Hepatic amoebiasis:**

It is characterized by tender liver and multiple abscesses scattered in the whole organ.

**Pulmonary amoebiasis:**

It is characterized by the appearance of single or multiple abscesses in one or both lungs.

**Cerebral amoebiasis:**

It is characterized by appearance of small abscess in one of the cerebral hemisphere.













**Splenic amoebiasis:**

In rare cases the parasite may enter into spleen to cause abscess.

**Cutaneous amoebiasis:**

It is characterized by the appearance of skin lesions.

**Urinogenital tract Infection:** *E. histolytica* may rarely enter into urinogenital tract through rectal fistula causing amoebic ulcer of the penis and vaginitis (Saritha, 2015).

Amebae						
	<i>Entamoeba histolytica</i>	<i>Entamoeba hartmanni</i>	<i>Entamoeba coli</i>	<i>Entamoeba polecki*</i>	<i>Endolimax nana</i>	<i>Iodamoeba bütschlii</i>
Trophozoite						
Cyst						

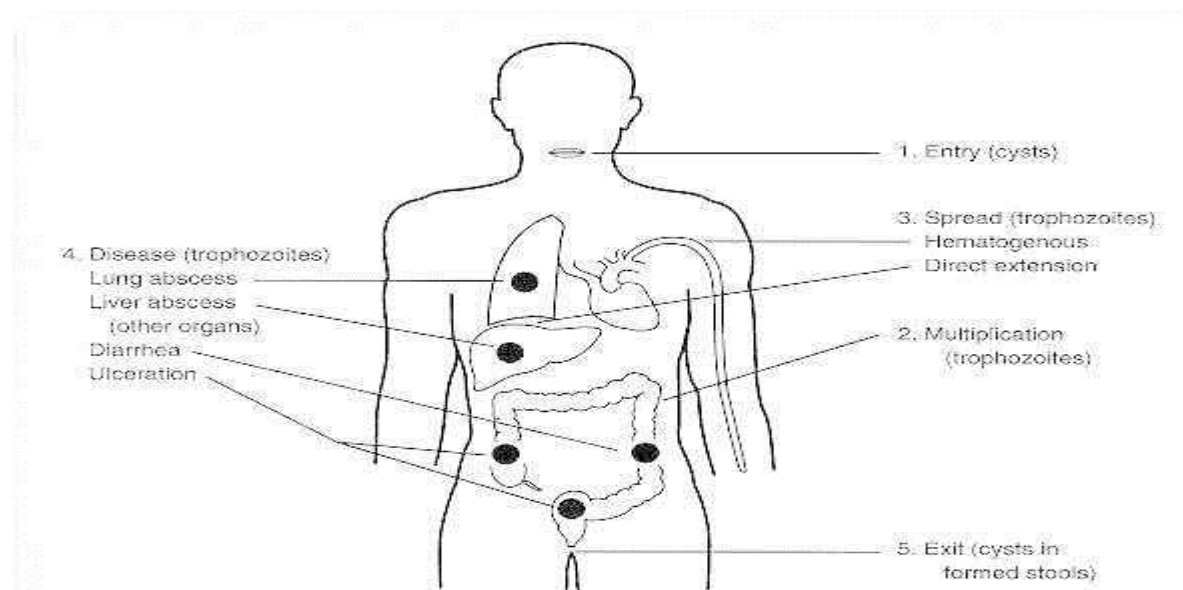
\*Rare, probably of animal origin

Figure 1.4: Amebas found in stool specimens of humans (Sodeman, 1996).



## 1.14 Clinical Manifestations

Figures 1.5 and 1.6 present an overview of the life cycle of the ameba and the pathogenesis of amebic infections. Pathogenic and non-pathogenic strains of *E. histolytica* inhabit the human digestive tract. Even pathogenic strains may live in the lumen as benign commensals. If mucosal invasion occurs, it may be limited to a few simple superficial erosions or it may progress to total involvement of the colonic mucosa with ulceration. Table 1.1 presents a World Health Organization classification of the clinical syndromes and related pathophysiologic mechanisms of *E. histolytica* infections. The clinical manifestations vary with the extent of involvement. Mucosal erosion causes diarrhea, which increases in severity with increasing area and depth of involvement. Symptoms are also affected by the site of the infection. The more distal the lesion in the colon, the greater the likelihood and severity of symptoms; thus small rectal lesions are more likely to be symptomatic than larger cecal lesions. Rectal bleeding is only slightly less common than diarrhea and is usually, but not invariably, associated with diarrhea. Such bleeding may be grossly apparent or may be occult and demonstrable only by chemical testing for blood. Urgency, tenesmus, cramping abdominal pain and tenderness may be present (Sodeman, 1996).



**Figure 1.5: Pathogenesis of *E. histolytica* infection (Sodeman, 1996).**

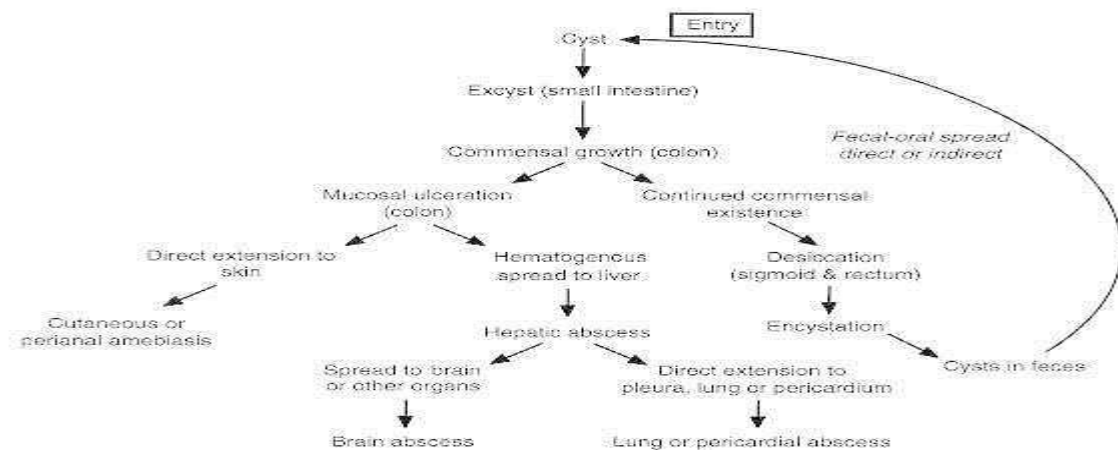


Figure 1.6: Multiplication and life cycle of *E histolytica* (Sodeman, 1996).

Table 1.1 Classification of Amebiasis

WHO clinical classification of Amebiasis Infection (modified)	Pathophysiologic Mechanism
Asymptomatic infection Symptomatic infection Intestinal amebiasis a. Amebic dysentery b. Non-dysentery gastroenteritis c. Ameboma d. Complicated intestinal amebiasis e. Post-amebic colitis	Colonization without tissue invasion Invasive infection  a. Fulminant ulcerative intestinal disease b. Ulcerative intestinal disease c. Proliferative intestinal disease d. Perforation, hemorrhage, fistula e. Mechanism unknown
Extra-intestinal amebiasis a. Non-specific hepatomegaly b. Acute non-specific infection  c. Amebic abscess d. Amebic abscess, complicated  e. Amebiasis cutis f. Visceral amebiasis	a. Intestinal infection with no demonstrable invasion b. Amebas in liver but without abscess c. Focal structural lesion d. Direct extension to pleura, lung, peritoneum or pericardium e. Direct extension to skin f. Metastatic infection of lung, spleen or brain.

The intestinal syndromes caused by *E histolytica* form a continuum ranging in severity from mild diarrhea to hemorrhagic dysentery. The span from mild to severe diarrhea is classified as non-dysentery colitis. Amebic dysentery has a dramatically different clinical presentation. The diarrhea is replaced by dysenteric stools consisting largely of pus and blood without feces. There is evidence of systemic toxicity with fever, dehydration, and electrolyte

abnormalities. Tenesmus and abdominal tenderness are regular features. This fulminant presentation may occur suddenly or evolve from less severe, pre-existing disease. Occasionally, and for no apparent reason, colonic infection with *E histolytica* will evoke a proliferative granulomatous response at an ulcer site. This infectious pseudotumor, called an *ameboma*, may become the leading point of an intussusception or may cause intestinal obstruction. This complication is uncommon (Sodeman, 1996).

Peritonitis as a result of perforation has been reported in connection with severe amebic colitis and, much less often, in patients with few or no symptoms. Other complications of intestinal amebiasis include colocutaneous fistula, perianal ulceration, urogenital infection, colonic stricture, intussusception, and hemorrhage. Most of these complications are uncommon and therefore may prove difficult to diagnose. The term post-amebic colitis is used for nonspecific colitis following a bout of severe acute amebic colitis. In such cases, the colon is free of parasites and the clinical findings resemble those of chronic ulcerative colitis (Sodeman, 1996).

Extra-intestinal amebiasis begins with hepatic involvement. Many patients with acute intestinal infection also have hepatomegaly, but in these cases amebas are not demonstrable in the liver and the pathogenesis of this hepatomegaly is not clear. A focal amebic abscess in the liver represents metastasis from intestinal infection. Symptomatic intestinal infection need not be present. The abscess appears as a slowly enlarging liver mass. Often the patient will have right upper quadrant pain, which may be referred to the right shoulder. If the abscess is located in a palpable portion of the liver, the area will be tender. Occasionally the enlarging abscess presses on the common bile duct and causes jaundice. If located under the dome of the diaphragm, the abscess may cause elevation of the dome of the diaphragm which presses on the right lung base, causing atelectasis and physical findings of consolidation. As the abscess nears the diaphragm the inflammation may stimulate pleural effusion (Sodeman, 1996).

Pleural, pulmonary, and pericardial infection occurs as a result of direct extension from the liver. Lung involvement is far more common than pericardial infection. Infection metastatic from the liver can involve other viscera or can give rise to a brain abscess. However, these complications are uncommon (Sodeman, 1996).

### **1.15 Structure**

*E histolytica* has a relatively simple life cycle that alternates between trophozoite and cyst stages (Figs. 4 and 5). The trophozoite is the actively metabolizing, mobile stage, and the cyst is dormant and environmentally resistant. Diagnostic concern centers on both stages (Fig. 3). Trophozoites vary remarkably in size—from 10 to 60  $\mu\text{m}$  or more in diameter, and when they are alive they may be actively motile. Amebas are anaerobic organisms and do not have mitochondria. The finely granular endoplasm contains the nucleus and food vacuoles, which in turn may contain bacteria or red blood cells. The parasite is sheathed by a clear outer ectoplasm. Nuclear morphology is best seen in permanent stained preparations. The nucleus has a distinctive central karyosome and a rim of finely beaded chromatin lining the nuclear membrane.

The cyst is a spherical structure, 10-20  $\mu\text{m}$  in diameter, with a thin transparent wall. Fully mature cysts contain four nuclei with the characteristic amebic morphology. Rod-like structures (chromatoidal bars) are present variably, but are more common in immature cysts. Inclusions in the form of glycogen masses also may be present. A number of non-pathogenic amebae can parasitize the human gastrointestinal tract and may cause diagnostic confusion. These include *Entamoeba hartmanni*, *Entamoeba gingivalis*, *Entamoeba coli*, *Endolimax nana*, and *Iodamoeba butschlii* (Fig. 3) (Sodeman, 1996).

### **1.16 Transmission**

*Entamoeba histolytica* can be transmitted a number of ways, but most commonly is it transferred from fecal matter, where *E. histolytica* cysts are present, to oral ingestion. It is also transmitted from contaminated food or water sources, which

are common in places such as Mexico, Central America, and South Asia. Some researchers have suggested a zoonosis pathway may also exist, but further studies still need to be conducted to prove this (Showler et al., 2013).

### **1.17 Genomic Diversity of Amoebiasis**

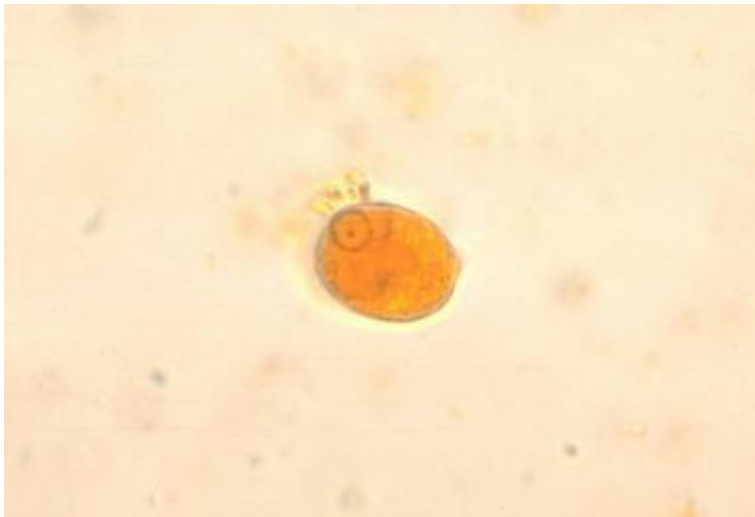Research on the genome of *E. histolytica* is an emerging area of importance in understanding the virulence of the parasite. In fact, recent studies have proposed that its genetic factors affect how infectious it is. The genomes of several strains of *E. histolytica* have been sequenced, which yielded interesting data about the amoeba. For example, it was discovered that about 75% of the genome consists of A and T nucleotides. Furthermore, among the strains sequenced nucleotide differences were low (single-nucleotide polymorphism ranged from 0.312 to 0.857 SNPs per kilobase). Conversely, other studies have found high diversity in the nucleotide repeats that separate tRNA genes or genes like that coding for SREHP, a protein consisting of a large amount of serine. However, gene copy number is diverse, suggesting that this could be an important part of the variety of virulence seen from the parasite.

Recent research provides evidence that *E. histolytica* reproduces sexually, a phenomena that has not yet been observed in the genus, Entamoeba. It was discovered that the particular strain of *E. histolytica*, HM-1:IMSS, contains most of the genes that contribute to meiosis. Thus, sexual reproduction probably provides a significant amount of the diversity observed in the genomes of the strains through events such as recombination and reassortment of alleles (Bruchhaus et al. 2012).

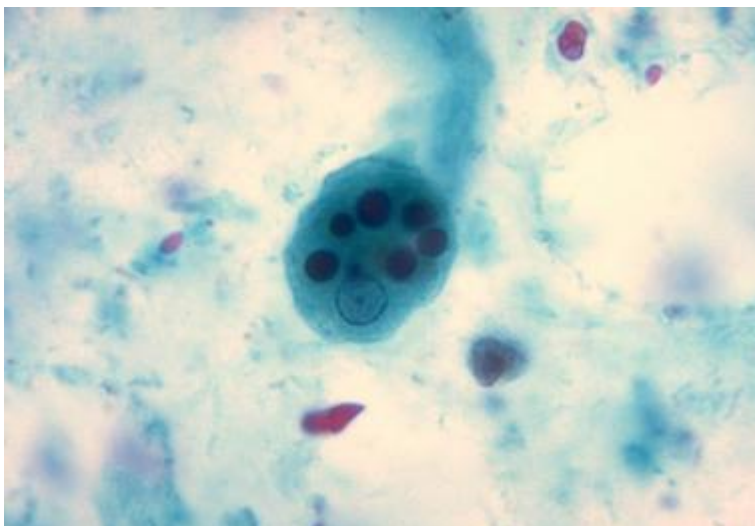
### **1.18 Pathophysiology**

*E. histolytica* is a pseudopod-forming, nonflagellated protozoal parasite that causes proteolysis and tissue lysis (hence the species name) and can induce host-cell apoptosis (see the image below). Humans and perhaps nonhuman primates are the only natural hosts.

Ingestion of *E histolytica* cysts (see the first image below) from the environment is followed by excystation in the terminal ileum or colon to form highly motile trophozoites (see the second image below). Upon colonization of the colonic mucosa, the trophozoite may encyst and is then excreted in the feces, or it may invade the intestinal mucosal barrier and gain access to the bloodstream, whereby it is disseminated to the liver, lung, and other sites. Excreted cysts reach the environment to complete the cycle.



**Figure 1.7:** *Entamoeba histolytica* cyst



**Figure 1.8:** *Entamoeba histolytica* trophozoite

Disease may be caused by only a small number of cysts, but the processes of encystation and excystation are poorly understood. The adherence of trophozoites to colonic epithelial cells seems to be mediated by a galactose/*N*-acetylgalactosamine (GAL/GalNAc)-specific lectin, a 260-kd surface protein

containing a 170-kd subunit and a 35-kd subunit. A mucosal immunoglobulin A (IgA) response against this lectin can result in fewer recurrent infections. Both lytic and apoptotic pathways have been described. Cytolysis can be undertaken by amebapores, a family of peptides capable of forming pores in lipid bilayers. Furthermore, in animal models of liver abscess, trophozoites induced apoptosis via a non-Fas and non-tumor necrosis factor (TNF)- $\alpha$ 1 receptor pathway. The amebapores, at sublytic concentrations, can also induce apoptosis.

Cysteine proteinases have been directly implicated in invasion and inflammation of the gut and may amplify interleukin (IL)-1-mediated inflammation by mimicking the action of human IL-1-converting enzyme, cleaving IL-1 precursor to its active form. The cysteine proteinases can also cleave and inactivate the anaphylatoxins C3a and C5a, as well as IgA and immunoglobulin G (IgG).

*E histolytica* possesses about 100 putative transmembrane kinases (TMKs), which are commonly divided into 9 subgroups. Of these, EhTMKB1-9 is expressed in proliferating trophozoites and induced by serum. In an animal model, it was found to be involved in phagocytosis and to play a role as a virulence factor in amebic colitis. These findings suggest that TMKs such as EhTMKB1-9 may be attractive targets for future drug development.

Epithelial cells also produce various inflammatory mediators, including IL-1 $\beta$ , IL-8, and cyclooxygenase (COX)-2, leading to the attraction of neutrophils and macrophages. Corticosteroid therapy is known to worsen the clinical outcome, possibly because of its blunting effect on this innate immune response. Additional host defenses, including the complement system, could be inhibited directly by the trophozoites, as is suggested by the finding that a region of the GAL/GalNAc-specific lectin showed antigenic crossreactivity with CD59, a membrane inhibitor of the C5b-9 attack complex in human red blood cells. Spread of amebiasis to the liver occurs via the portal blood. The pathogenic strains evade the complement-mediated lysis in the bloodstream. Trophozoites that reach the liver create unique abscesses with well-circumscribed regions of

dead hepatocytes surrounded by few inflammatory cells and trophozoites and unaffected hepatocytes. These findings suggest that *E histolytica* organisms are able to kill hepatocytes without direct contact.

Serum antibodies in patients with amebic liver abscess develop in 7 days and persist for as long as 10 years. A mucosal IgA response to *E histolytica* occurs during invasive amebiasis; however, no evidence suggests that invasive amebiasis is increased in incidence or severity in patients with IgA deficiency.

Cell-mediated immunity is important in limiting the disease and preventing recurrences. Antigen-specific blastogenic responses occur, leading to production of lymphokines, including interferon-delta, which activates the killing of *E histolytica* trophozoites by the macrophages. This killing depends on contact, oxidative pathways, nonoxidative pathways, and nitric oxide (NO).

Lymphokines, such as TNF- $\alpha$ , are capable of activating the amebicidal activity of neutrophils. Incubation of CD8<sup>+</sup> lymphocytes with *E histolytica* antigens in vitro elicits cytotoxic T-cell activity against the trophozoites. During acute invasive amebiasis, T-cell response to *E histolytica* antigens is depressed by a parasite-induced serum factor (Vinod, 2015).

### **1.19 Etiology**

Amebiasis is a parasitic infection caused by the protozoal organism *E histolytica*, which can give rise both to intestinal disease (eg, colitis) and to various extraintestinal manifestations, including liver abscess (most common) and pleuropulmonary, cardiac, and cerebral dissemination.

The genus *Entamoeba* contains many species, some of which (ie, *E histolytica*, *Entamoeba dispar*, *Entamoeba moshkovskii*, *Entamoeba polecki*, *Entamoeba coli*, and *Entamoeba hartmanni*) can reside in the human interstitial lumen. Of these, *E histolytica* is the only one definitely associated with disease; the others are considered nonpathogenic. Studies have recovered *E dispar* and *E moshkovskii* from patients with gastrointestinal (GI) symptoms, but whether these species cause these symptoms remains to be determined.



Although *E dispar* and *E histolytica* cannot be differentiated by means of direct examination, molecular techniques have demonstrated that they are indeed 2 different species, with *E dispar* being commensal (as in patients with HIV infection) and *E histolytica* pathogenic. It is currently believed that many individuals with *Entamoeba* infections are actually colonized with *E dispar*, which appears to be 10 times more common than *E histolytica*; however, in certain regions (eg, Brazil and Egypt), asymptomatic *E dispar* and *E histolytica* infections are equally prevalent.—In Western countries, approximately 20%-30% of men who have sex with men are colonized with *E dispar*.

*E histolytica* is transmitted primarily through the fecal-oral route. Infective cysts can be found in fecally contaminated food and water supplies and contaminated hands of food handlers. Sexual transmission is possible, especially in the setting of oral-anal practices (anilingus). Poor nutrition, through its effect on immunity, has been found to be a risk factor for amebiasis (Vinod, 2015).

## **1.20 Treatment**

In endemic areas, asymptomatic infections are not treated. In nonendemic areas, however, asymptomatic infection should be treated; luminal agents that are minimally absorbed by the GI tract (eg, paromomycin, iodoquinol, and diloxanidefuroate) are best suited for such therapy. This recommendation is based on 2 arguments: first, that invasive disease may develop, and second, that shedding of *E histolytica* cysts in the environment is a public health concern.

Asymptomatic *E dispar* infections should not be treated, but because this organism is a marker of fecal-oral contamination, educational efforts should be initiated.

Metronidazole is the mainstay of therapy for invasive amebiasis. Tinidazole has been approved by the US Food and Drug Administration (FDA) for intestinal or extraintestinal amebiasis. Other nitroimidazoles with longer half-lives (ie, secnidazole and ornidazole) are currently unavailable in the United States.

Nitroimidazole therapy leads to clinical response in approximately 90% of patients with mild-to-moderate amebic colitis. Because intraluminal parasites are

not affected by nitroimidazoles, nitroimidazole therapy for amebic colitis should be followed by treatment with a luminal agent (eg, paromomycin or diloxanidefuroate) to prevent a relapse (Vinod, 2015).

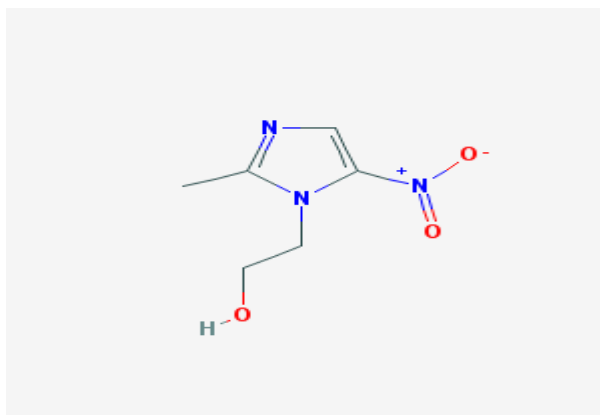
Amebic liver abscess of up to 10 cm can be cured with metronidazole without drainage. Clinical defervescence (the period of abatement of fever) should occur during the first 3-4 days of treatment. Failure of metronidazole therapy may be an indication for surgical intervention. Treatment with a luminal agent should also follow.

Chloroquine has also been used for patients with hepatic amoebiasis. Dehydroemetine has been successfully used but, because of its potential myocardial toxicity, is not preferred (Vinod, 2015).

Broad-spectrum antibiotics may be added to treat bacterial super infection in cases of fulminant amebic colitis and suspected perforation. Bacterial coinfection of amebic liver abscess has occasionally been observed (both before and as a complication of drainage), and adding antibiotics to the treatment regimen is reasonable in the absence of a prompt response to nitroimidazole therapy (Vinod, 2015).

## 1.21 Metronidazole

Metronidazole is a nitroimidazole used to treat amebiasis; vaginitis; trichomonas infections; giardiasis; anaerobic bacteria; and treponemal infections. It has also been proposed as a radiation sensitizer for hypoxic cells.



## **Chemical structure: Metronidazole**

### **IUPAC Name**

2-(2-methyl-5-nitroimidazol-1-yl) ethanol

### **Drug Indication of Metronidazole**

For the treatment of anaerobic infections and mixed infections, surgical prophylaxis requiring anaerobic coverage, Clostridium difficile-associated diarrhea and colitis, Helicobacter pylori infection and duodenal ulcer disease, bacterial vaginosis, Giardia lamblia gastro-enteritis, amebiasis caused by *Ehistolytica*, acne rosacea (topical treatment), and Trichomonas infections (McEvoy, 2006).

### **Drug Tolerance of Metronidazole**

Natural and acquired resistances to metronidazole have been reported occasionally in some strains of *Trichomonas vaginalis*. Although the clinical importance is unclear, *In vitro* studies indicate that while some *T. vaginalis* isolates with reduced susceptibility to metronidazole also have reduced susceptibility to tinidazole, the minimum lethal concentration (MLC) of tinidazole for these strains may be lower than the MLC of metronidazole (McEvoy, 2006). Rarely, resistance to the drug also has been reported in *Bacteroides fragilis* and other anaerobic bacteria following long-term therapy. There has been at least one report of a strain of metronidazole-resistant *B. fragilis* that was cross-resistant *in vitro* to amoxicillin and clavulanate potassium, imipenem, and tetracycline; the strain was susceptible to chloramphenicol and clindamycin *in vitro*. Resistance to metronidazole may be due to poor cell penetration and/or decreased nitroreductase activity (McEvoy, 2006).

### **Pharmacology of Metronidazole**

Metronidazole, a synthetic antibacterial and antiprotozoal agent of the nitroimidazole class, is used against protozoa such as *Trichomonas vaginalis*, amebiasis, and giardiasis. Metronidazole is extremely effective against anaerobic

bacterial infections and is also used to treat Crohn's disease, antibiotic-associated diarrhea, and rosacea.

Metronidazole is a synthetic nitroimidazole derivative with antiprotozoal and antibacterial activities. Although its mechanism of action is not fully elucidated, un-ionized metronidazole is readily taken up by obligate anaerobic organisms and is subsequently reduced by low-redox potential electron-transport proteins to an active, intermediate product. Reduced metronidazole causes DNA strand breaks, thereby inhibiting DNA synthesis and bacterial cell growth (NCI term browser, 2016).

### **Absorption, Distribution and Excretion of Metronidazole**

Metronidazole is well absorbed orally; bioavailability is at least 80%. It is distributed to saliva, bile, seminal fluid, breast milk, bone, liver and liver abscesses, lungs, and vaginal secretions; it crosses the placenta and blood-brain barrier (Thomson, 2006).

At least 80% of an oral dose of metronidazole is absorbed from the GI tract. The rate of absorption and peak plasma concentrations of metronidazole are decreased when conventional tablets or capsules of the drug are administered with food; however, the total amount of drug absorbed is not affected (McEvoy, 2006).

### **Metabolism of Metronidazole**

Approximately 30-60% of an oral or IV dose of metronidazole is metabolized in the liver by hydroxylation, side-chain oxidation, and glucuronide conjugation. The major metabolite, 2-hydroxy metronidazole, has some antibacterial and antiprotozoal activity.

Four other nitro-group-containing metabolites have been identified, each derived from side-chain oxidation of ethyl and/or methyl group. They include 1-acetic acid-2-methyl-5-nitroimidazole and 1-(2-hydroxyethyl)-2-carboxylic acid-5-nitroimidazole salt.

The liver is the main site of metabolism, and this accounts for over 50% of the systemic clearance of metronidazole. The 2 principal metabolites result from oxidation of side chains, a hydroxy derivative and an acid. The hydroxy metabolite has a longer half-life (about 12 hr) and nearly 50% of the antitrichomonal activity of metronidazole. Formation of glucuronides also is observed. Small quantities of reduced metabolites, including ring-cleavage products, are formed by the gut flora. The urine of some patients may be reddish-brown owing to the presence of unidentified pigments derived from the drug (Hardman et al, 2001).

### **Biological Half-Life of Metronidazole**

The plasma half-life of metronidazole is reported to be 6-8 hours in adults with normal renal and hepatic function. In one study using radiolabeled metronidazole hydrochloride, the half-life of unchanged metronidazole averaged 7.7 hours and the half-life of total radioactivity averaged 11.9 hours. The plasma half-life of metronidazole is not affected by changes in renal function; however, the half-life may be prolonged in patients with impaired hepatic function. It has been observed from a study that half-life of metronidazole averaged 18.3 hours in adults with alcoholic liver disease and impaired hepatic function, (range: 10.3-29.5 hours) (McEvoy, 2006).

### **Mechanism of Action of Metronidazole**

Metronidazole is microbicidal, it is active against most obligate anaerobic bacteria and protozoa by undergoing intracellular chemical reduction via mechanisms unique to anaerobic metabolism. Reduced metronidazole, which is cytotoxic but short-lived, interacts with DNA to cause loss of helical structure, strand breakage, and resultant inhibition of nucleic acid synthesis and cell death (Thomson, 2006).

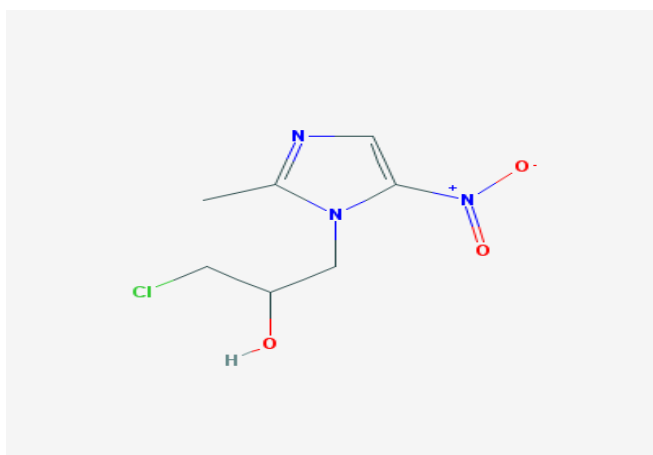
Metronidazole is bactericidal, amebicidal, and trichomonacidal in action. The exact mechanism of action of the drug has not been fully elucidated. Metronidazole is un-ionized at physiologic pH and is readily taken up by anaerobic organisms or cells. In susceptible organisms or cells, metronidazole is reduced by low-redox-potential electron transport proteins (e.g., nitroreductases

such as ferredoxin) to unidentified polar product(s) which lack the nitro group. The reduction product(s) appears to be responsible for the cytotoxic and antimicrobial effects of the drug which include disruption of DNA and inhibition of nucleic acid synthesis. Metronidazole is equally effective against dividing and nondividing cells (McEvoy, 2006).

Metronidazole is a prodrug. Unionized metronidazole is selective for anaerobic bacteria due to their ability to intracellularly reduced metronidazole to its active form. This reduced metronidazole then covalently binds to DNA, disrupt its helical structure, inhibiting bacterial nucleic acid synthesis and resulting in bacterial cell death.

## 1.22 Ornidazole

Ornidazole is a nitroimidazole antiprotozoal agent used in ameba and trichomonas infections. It is partially plasma-bound and also has radiation-sensitizing action.



**Chemical structure: Ornidazole**

### Pharmacology of Ornidazole

Ornidazole is rapidly absorbed from the GI tract and peak plasma concentrations of about 30 mgm per ml have been achieved within 2 hours of a single dose of 1.5 gm, falling to about 9 mgm per ml after 24 hours and 2.5 mgm per ml after 48 hours. The plasma elimination half-life is 12-14 hours. Less than 15% is bound to plasma proteins. Ornidazole is widely distributed in body tissues and fluids, including the cerebrospinal fluid. It is extensively metabolised

in the liver (95%) and excreted in the urine, mainly as conjugates and metabolites, and to a lesser extent in the faeces. Biliary excretion is important in the elimination of ornidazole and its metabolites ([www.squarepharma.com.bd/downloads/Robic.pdf](http://www.squarepharma.com.bd/downloads/Robic.pdf)).

### **Mechanism of Action of Ornidazole**

Ornidazole is a nitro imidazole which has broad spectrum activity against protozoa and some anaerobic bacteria. Its selective toxicity to anaerobic microbes involves

1. Drug enters the cell by diffusion,
2. Nitro group of drug is reduced by redox proteins present only in anaerobic organisms to reactive nitro radical which exerts cytotoxic action by damaging DNA and other critical biomolecules.
3. DNA helix destabilization & strand breakage has been observed.

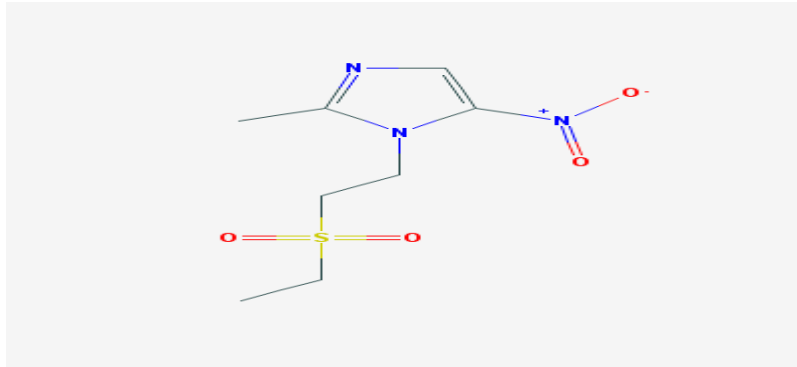
([https:// www.medicineindia.org](https://www.medicineindia.org))

### **Pharmacokinetics of Ornidazole**

Absorption: Well absorbed orally, Distribution: Widely distributed, Metabolism: Metabolized in liver by conjugation, Excretion: Excreted in urine and small portion is excreted in bile ([www.medicineindia.org](http://www.medicineindia.org)).

### **1.23 Tinidazole**

Tinidazole is a nitroimidazole antitrichomonal agent effective against *Trichomonas vaginalis*, *Entamoeba histolytica*, and *Giardia lamblia* infections. Tinidazole is a nitroimidazole antimicrobial. The chemical classification of tinidazole is Nitroimidazoles. Tinidazole is a 5-nitroimidazole derivative with antiprotozoal property (Thomson, 2006).



### **Chemical structure: Tinidazole**

Tinidazole is used for the treatment of trichomoniasis caused by *T. vaginalis* in both female and male patients. It is also used for the treatment of giardiasis caused by *G. duodenalis* in both adults and pediatric patients older than three years of age. Another use of tinidazole is to treat intestinal amoebiasis and amoebic liver abscess caused by *E. histolytica* in both adults and pediatric patients older than three years of age (Thomson, 2006).

### **Pharmacology of Tinidazole**

Tinidazole is a synthetic antiprotozoal agent. It demonstrates activity both *in vitro* and in clinical infections against the following protozoa: *Trichomonas vaginalis*, *Giardia duodenalis* (also termed *G. lamblia*), and *Entamoeba histolytica*. Tinidazole does not appear to have activity against most strains of *Vaginal lactobacilli*. Although the mechanism of action has not been fully elucidated, it has been suggested that tinidazole is metabolized and yields nitrite anions and metronidazole. Metronidazole's nitro group in turn is reduced via the parasite ferredoxin, thereby generating a series of free nitro radicals including nitro anions. Toxicity is achieved via depletion of sulfhydryl groups and DNA strand breaks with multiple hits having an additive effect and ultimately leading to cell death (Thomson, 2006).

### **Absorption, Distribution and Excretion of Tinidazole**

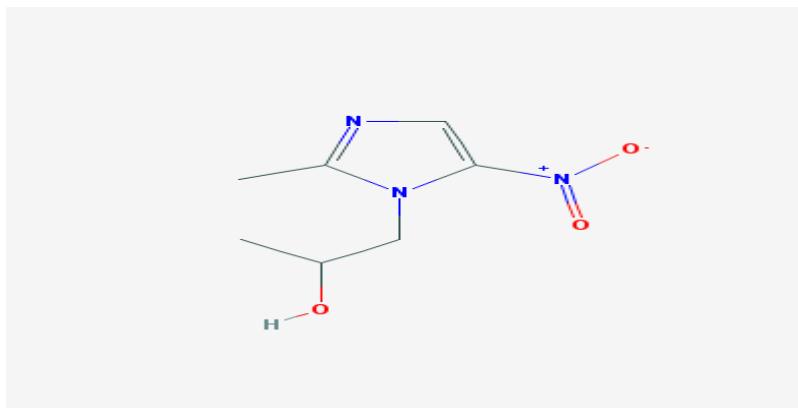
Tinidazole is distributed into virtually all tissues and body fluids. It crosses the blood-brain barrier, placental barrier and is distributed into breast milk. Volume of distribution (Vd) is about 50 L. Under fasting conditions tinidazole is rapidly



and completely absorbed. Administration with food resulted in a delay in  $T_{max}$  of approximately 2 hours and a decline in  $C_{max}$  of approximately 10% and an AUC of  $901.6 \pm 126.5 \mu\text{ghr/mL}$  (Thomson, 2006) Time to peak concentration: 1.6 ( $\pm 0.7$  hours) (Thomson, 2006).

### 1.24 Secnidazole

Secnidazole is a nitroimidazole derivative and it has antiprotozoal activity.



**Chemical structure: Secnidazole**

#### Mechanism of Action of Secnidazole

Secnidazole is a nitroimidazole which has broad spectrum activity against Protozoa and some anaerobic bacteria. Its selective toxicity to anaerobic microbes involves:

1. Drug enters the cell by diffusion,
2. Nitro group of drug is reduced by redox proteins present only in anaerobic organisms to reactive nitro radical which exerts cytotoxic action by damaging DNA and other critical biomolecules.
3. DNA helix destabilization & strand breakage has been observed ([www.medicineindia.org](http://www.medicineindia.org)).

#### Pharmacokinetics of Secnidazole

**Absorption:** Secnidazole is absorbed orally.

**Distribution:** It is widely distributed throughout the body.

**Metabolism and Excretion:** Secnidazole is metabolized in liver and is excreted in urine ([www.medicineindia.org](http://www.medicineindia.org)).

Spreading of the infection by *E. histolytica* in developing nations is mainly due to the contaminated water and food. Areas with inadequate sanitation is also one of the the leading causes of amoebiasis. Protozoan disease caused by *E. histolytica* has impact on travelers visiting the endemic area.

Metronidazole is currently the drug of choice for treating invasive amoebiasis in adults and children. The standard regimen of metronidazole for the treatment of amoebic colitis is 500 to 750 mg given three times daily in adults and 30 to 50 mg/kg/day in children given for five to 10 days. This treatment is often followed by the treatment with paromomycin for eliminating the cyst from the colon. However, improved dosing schedules have been observed with other antiamoebic drugs, such as tinidazole and ornidazole. Tinidazole and ornidazole have longer half-lives that allow shorter periods of treatment. Two gram tinidazole once daily for 3 days is used for the treatment of amoebic dysentery. For ornidazole the adult dose is 1.5 gm as single daily dose for three days. Another antiamoebic drug, secnidazole is better tolerated when compared to metronidazole. Shorter period of treatment is another advantage of secnidazole treatment. These drugs have been used as an alternative antiamoebic drugs.

Unfortunately metronidazole resistance for the treatment of amoebic dysentery is an increasing concern (Jarrad, 2016). Moreover, it has been described that the trophozoites of *E histolytica* can be adapted to grow in presence of therapeutic concentration of metronidazole. Thus producing resistance strains of the parasites. It has been shown from a systemic review that the adverse effects of metronidazole occurred with conventional dose which include nausea, nausea associated with hypersalivation, anorexia, dizziness etc (Marie, 2013). Another study revealed that during metronidazole treatment, loss of sight, vertigo, ataxia, and headache occurred as adverse effects in 3 years old child (Kafadar, 2013). The adverse effects associated with metronidazole treatment in some patients, and the possibility of parasite resistance to metronidazole is of major concern to treat the illness. Therefore, it is now an important concern to develop other treatment options to combat parasitic infection caused by *E histolytica* (Wassmann, 1999).

To reduce the side effects and the risk of developing resistance, combination regimens of antiamoebic drugs might have advantages. The benefits of using combination regimens of anti-amoebic drugs over monotherapy and single-dose regimens over longer regimens have not been tested yet.

In the present study an attempt has been made to use the combination regimens of antiamoebic drugs against the growth of *E. histolytica*.

### **1.25 Objective:**

The objective of the present study is to determine the sensitivity of the combination regimens of anti-amoebic drugs against clinical isolates of *E. histolytica*.

### **1.26 Aim of the study**

For treating invasive amoebiasis in adults and children, metronidazole is presently the drug of choice. However, it may be insufficient to eliminate parasite cysts in the intestine with the treatment of metronidazole alone. Some unpleasant adverse effects associated with metronidazole in some patients, and the possibility of parasite resistance to metronidazole has to be considered. In this study the concentration of metronidazole and other antiamoebic drug are reduced to an extent for inhibiting the growth of *E. histolytica*. The aim of this experiment is to inhibit the growth of *E. histolytica* from the clinical isolates by using different combination regimens of-

- metronidazole and ornidazole
- metronidazole and tinidazole
- metronidazole and secnidazole.

## Chapter Two: Material and Method

### 2.1. Collection of sample

Metronidazole, ornidazole, tinidazole and secnidazole tablets were randomly collected from different Pharmaceutical Industry of Bangladesh. The samples were properly checked for their physical appearance, name of the manufacturer, batch number, manufacturing date, expiry date, manufacturing license number, D.A.R. number and maximum retail price at the time of purchase. This investigation was performed in the microbiology Laboratory, East west University, Bangladesh during August, 2015 to March, 2016.

### 2.2 Preparation of antimicrobial agents

The metronidazole tablets were crushed and weighed then dissolved in distilled water. The concentration was maintained 48mg/ml. The stock solution was stored in a refrigerator.

Stock solution of ornidazole, tinidazole, secnidazole metronidazole+ornidazole metronidazole+tinidazole and metronidazole+secnidazole were prepared in the same manner.

### 2.3 Clinical isolates

Clinical isolates of *E. histolytica* were harvested from 24 hours old cultures and suspended in a LYI-S-2 medium. Axenic medium (LYI-S-2) consists of liver digest, yeast extract, iron, serum. The parasite count was adjusted to  $3 \times 10^6$  parasites/ml in medium by haemocytometer (Mukhopadhyay, R.M, et al., 1996; Bansal, D. et al., 2004). Isolation is usually achieved by growing the species in an environment that was previously sterilized, and was thereby rid of contaminating organisms. This isolation was performed in the Parasitology Laboratory, Laboratory Sciences Division, International Centre for Diarrhoeal Disease Research, Bangladesh (icddr,b).

### 2.4 The instruments

- 1) Analytical balance
- 2) Morter and pastle

- 3) Vortex machine
- 4) Micropipettes
- 5) Eppendorf
- 6) Microtiter plate
- 7) Microscope
- 8) Haemocytometer
- 9) Microtips
- 10) Incubator
- 11) Autoclave
- 12) Laminar flow
- 13) Beaker

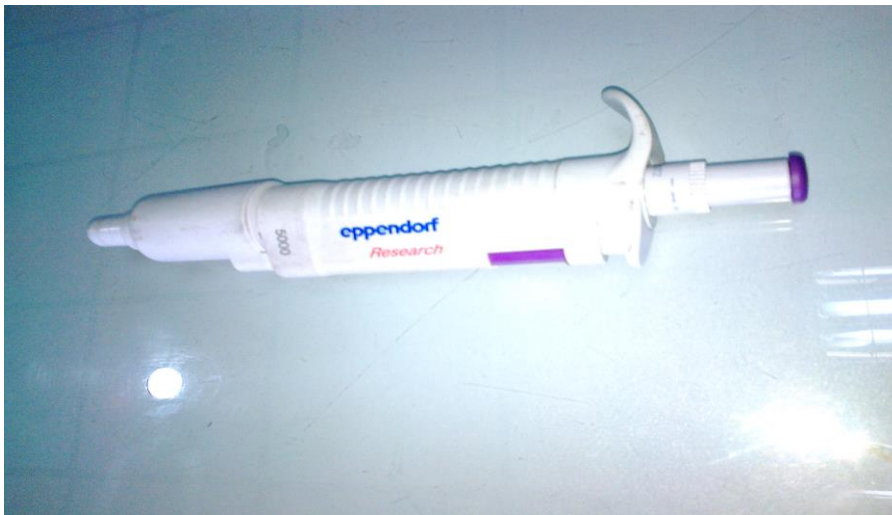

Figure 2.1: Micropipette



Figure 2.2: Analytical balance

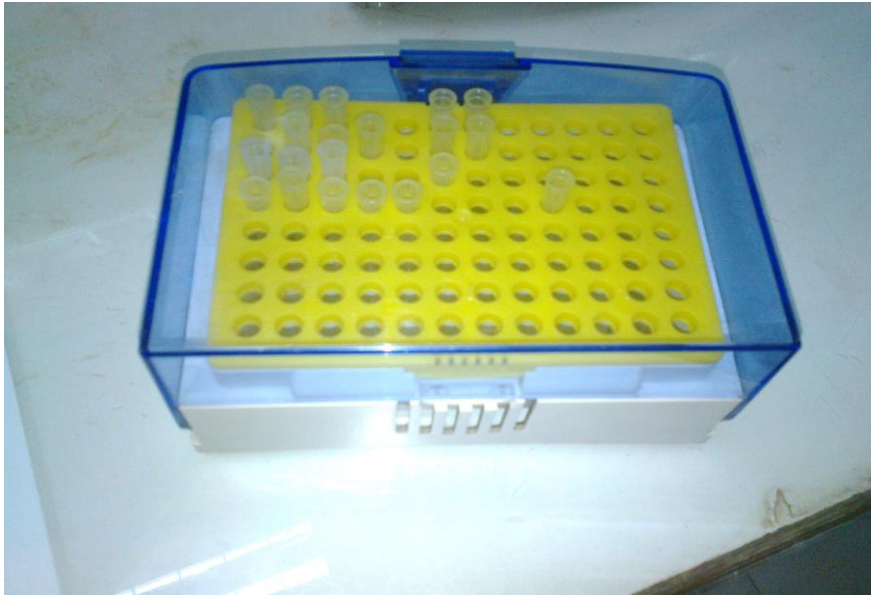

Figure 2.3: Microtips holder



Figure 2.4: Microtiter plate



Figure 2.5: Laminar flow



Figure 2.6: Microscope



Figure 2.7: Incubator



Figure 2.8: Haemacytometer





Figure 2.9: Autoclave

## 2.5 In vitro drug sensitivity assay

### 1) Metronidazole, Ornidazole and Metronidazole+Ornidazole

Drug sensitivity assay of the samples was carried out by using microtiter plates. In wells (A-1) to (F-1), 50  $\mu$ l medium was added, then in (B-1), 50  $\mu$ l metronidazole stock solution was added and serial dilutions of the drugs were performed down {(B-1) to (F-1)} the plate mixed properly. 50  $\mu$ l of the medium from the well (F-1) was discarded to maintain the equality of the concentration of the drugs. Further 50  $\mu$ l of parasite suspension ( $3 \times 10^6$  parasites/ml) was added to all the wells {(A-1) to (F-1)}. The final concentrations of the drugs were 12, 6, 3 and 1.5 mg/ml. Well (A-1) was control (medium only). Same procedure was performed on column 2 and 3 for ornidazole and ornidazole+metronidazole. Then plastic strip was used to cover the plate. Plates were incubated at 37°C. After 4 hours the plate was taken from the incubator. Then the viable parasites were counted by haemocytometer under microscope in each of the wells.

## **2) Metronidazole, Tinidazole and Metronidazole+Tinidazole**

Drug sensitivity assay of the samples was carried out by using microtiter plates. In wells (A-1) to (F-1), 50 µl medium was added, then in (B-1), 50 µl metronidazole stock solutions was added and serial dilutions of the drugs were performed down {(B-1) to (F-1)} the plate mixed properly. 50 µl of the medium from the well (F-1) was discarded to maintain the equality of the concentration of the drugs. Further 50 µl of parasite suspension ( $3 \times 10^6$  parasites/ml) was added to all the wells {(A-1) to (F-1)}. The final concentrations of the drugs were 12, 6, 3 and 1.5 mg/ml. Well (A-1) was control (medium only). Same procedure was performed on column 2 and 3 for tinidazole and tinidazole+metronidazole. Then plastic strip was used to cover the plate. Plates were incubated at 37°C. After 4 hours the plate was taken from the incubator. Then the viable parasites were counted by haemocytometer under microscope in each of the wells.

## **3) Metronidazole, secnidazole and Metronidazole+secnidazole**

Drug sensitivity assay of the samples was carried out by using microtiter plates. In wells (A-1) to (F-1), 50 µl medium was added, then in (B-1), 50 µl metronidazole stock solution was added and serial dilutions of the drugs were performed down {(B-1) to (F-1)} the plate mixed properly. 50 µl of the medium from the well (F-1) was discarded to maintain the equality of the concentration of the drugs. Further 50 µl of parasite suspension ( $3 \times 10^6$  parasites/ml) was added to all the wells {(A-1) to (F-1)}. The final concentrations of the drugs were 12, 6, 3 and 1.5 mg/ml. Well (A-1) was control (medium only). Same procedure was performed on column 2 and 3 for secnidazole and secnidazole + metronidazole. Then plastic strip was used to cover the plate. Plates were incubated at 37°C. After 4 hours the plate was taken from the incubator. Then the viable parasites were counted by haemocytometer under microscope in each of the wells.

## Chapter Three: Result and Discussion

### 3.1 Viable count of clinically isolates *E. histolytica* from Metronidazole, Ornidazole and their Combination after 4 hours of incubation

The initial count of the parasite was  $3 \times 10^6$  parasites/ml. After 4 hours the parasites count of the control was  $1.6 \times 10^6$  parasites/ml. The number of parasites was decreased in the control after 4 hours of incubation.

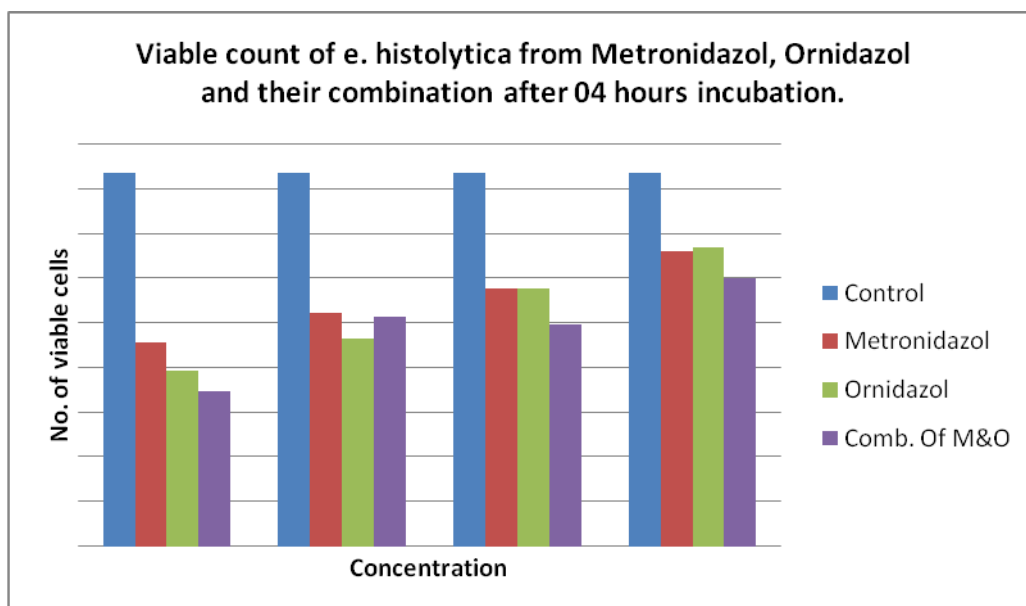
**Table 3.1: Viable count of *E. histolytica* in Metronidazole, Ornidazole and their Combination after 4 hours of incubation**

Concentration (mg/ml)	Metronidazole	Ornidazole	Combination
12	91±31*	79±47*	69±42*
6	104±26*	93±35*	103±26*
3	115±29*	115±34*	99±27*
1.5	132±20	134±18	120±23*

All the data are compared with control.

Values are expressed as Mean ±SD (n=72). \*p<0.05 is used as level of significance. After 4 hours incubation, when the concentration of Metronidazole, Ornidazole and combination was 1.5 mg/ml the viable count of *E. histolytica* were 132, 134 and 120 respectively. When the concentrations were 3 mg/ml, the viable count of *E. histolytica* was 115 (metronidazole), 115 (ornidazole) and 99 (combination) respectively. The viable count of *E. histolytica* was 104, 93 and 103 after treatment with 6 mg/ml of metronidazole alone, ornidazole alone and the combination of metronidazole and ornidazole respectively. When the concentration of metronidazole, ornidazole and combination were 12 mg/ml, the viable count of *E. histolytica* was 91, 79 and 69 respectively.

Combination of ornidazole and metronidazole at the concentration of 3, 6 and 12mg/ml is statistically significant (p<0.05) to inhibit the growth of *E. histolytica* when compared with the control. At the concentration of 1.5 mg/ml, only combination of metronidazole and ornidazole is significantly different when compared with the control (p<0.05). Metronidazole and ornidazole do not show any significant inhibition of parasite counts when compared to the control.



**Figure 3.1: Viable count of *E. histolytica* from Metronidazol, Ornidazol and their combination after 04 hours incubation.**

From the above graph it can be concluded that the viable count of *E. histolytica* has decreasing trend with the increase of concentration of drugs.

### **3.2 Viable count of clinically isolates *E. histolytica* from Metronidazole, Tinidazole and their Combination after 4 hours of incubation**

The initial count of the parasite was  $3 \times 10^6$  parasites/ml. After 4 hours the parasites count of the control was  $1.5 \times 10^6$  parasites/ml. The number of parasites was decreased in the control after 4 hours of incubation.

**Table 3.2: Viable count of *E. histolytica* in Metronidazole, Tinidazole and their Combination after 4 hours of incubation**

Concentration (mg/ml)	Metronidazole	Tinidazole	Combination
12	100±26	75±37*	68±43*
6	116±24	95±33*	86±35*
3	129±26	97±35*	101±28
1.5	143±23	119±41	106±29

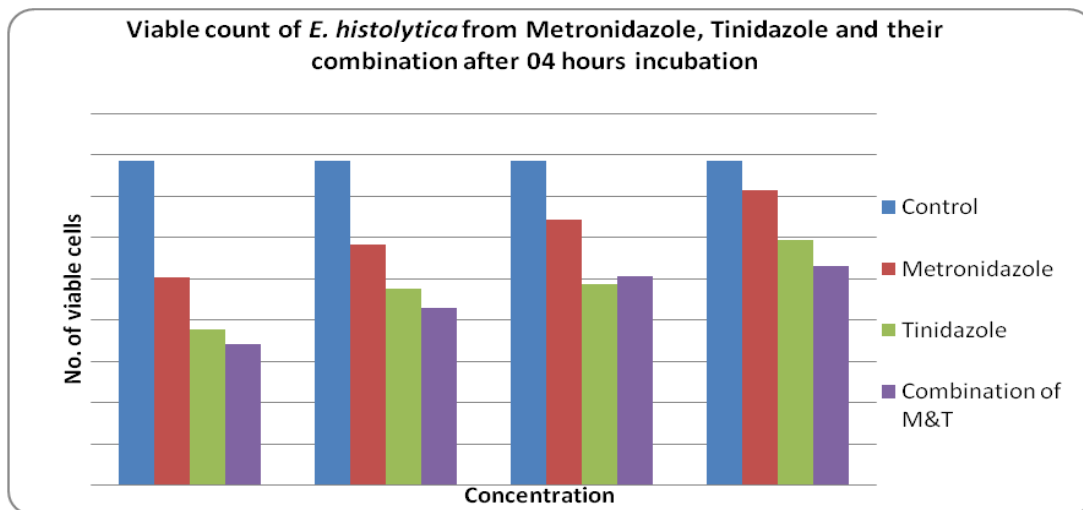
All the data are compared with control.

Values are expressed as Mean ±SD (n=72). \*p<0.05 is used as level of significance.

After 4 hours incubation, when the concentration of Metronidazole, Tinidazole and Combination was 1.5 mg/ml the viable count of *E. histolytica* were 143, 119 and 106 respectively. When the concentrations were 3 mg/ml, the viable count of *E. histolytica* was 129 (metronidazole), 97 (tinidazole) and 101 (combination)

respectively. The viable count of *E. histolytica* was 116, 95 and 86 after treatment with 6 mg/ml of metronidazole alone, tinidazole alone and the combination of metronidazole and ornidazole respectively. When the concentrations of metronidazole, tinidazole and combination were 12 mg/ml, the viable count of *E. histolytica* was 100, 75 and 68 respectively.

Combination of tinidazole and metronidazole at the concentration of 6 and 12mg/ml is statistically significant ( $p < 0.05$ ) to inhibit the growth of *E. histolytica* when compared with the control. At the concentration of 3mg/ml, only tinidazole is significantly different when compared with the control.



**Figure 3.2: Viable count of *E. histolytica* from Metronidazole, Tinidazole and their combination after 04 hours incubation**

From the above graph it can be concluded that the viable count of *E. histolytica* has decreasing trend with the increase of concentration of drugs.

### **3.3 Viable count of clinically isolates *E. histolytica* from Metronidazole, Secnidazole and their Combination after 4 hours of incubation**

The initial count of the parasite was  $3 \times 10^6$  parasites/ml. After 4 hours the parasites count of the control was  $1.9 \times 10^6$  parasites/ml. The number of parasites was decreased in the control after 4 hours of incubation.

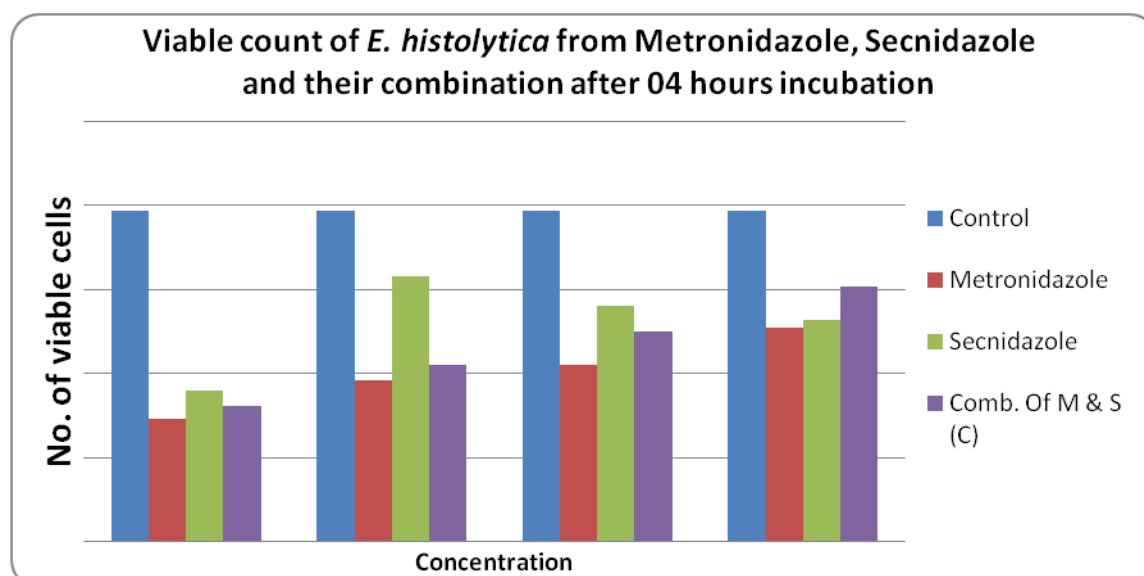
**Table 3.3: Viable count of *E. histolytica* in Metronidazole, Secnidazole and their Combination after 4 hours of incubation**

Concentration (mg/ml)	Metronidazole	Secnidazole	Combination
12	73±69	89±55	80±58
6	95±53	157±42	104±52
3	105±48	139±53	124±43
1.5	126±46	131±34	151±56

All the data are compared with control.

Values are expressed as Mean ±SD (n=36). The result is not statistically significant. After 4 hours incubation, when the concentration of Metronidazole, Secnidazole and Combination was 1.5 mg/ml the viable count of *E. histolytica* were 126, 131 and 151. When the concentration was 3 mg/ml, the viable count of *E. histolytica* was 126 (metronidazole) , 131(secnidazole) and 151 (combination) respectively. The viable count of *E. histolytica* was 95, 157 and 104 after treatment with 6 mg/ml of metronidazole alone, secnidazole alone and the combination of metronidazole and secnidazole respectively. When the concentrations of metronidazole, secnidazole and combination were 12 mg/ml, the viable count of *E. histolytica* was 73, 89 and 80 respectively.

Combination of secnidazole and metronidazole at the concentration of 1.5, 3, 6 and 12mg/ml is statistically insignificant (p<0.05) to inhibit the growth of *E. histolytica* when compared with the control.



**Figure 3.3: Viable count of *E. histolytica* from Metronidazole, Secnidazole and their combination after 04 hours incubation**

From the above graph it can be concluded that the viable count of *E. histolytica* has decreasing trend with the increase of concentration of drugs.

### 3.4 Discussion

*Entamoeba histolytica* is a protozoan parasite responsible for amoebiasis. Large intestine is usually infected by *E histolytica* and internal inflammation occurs. Fifty million people are infected by *E histolytica* worldwide, mostly in tropical countries in areas of poor sanitation. Most *Entamoeba histolytica* infections are asymptomatic and trophozoites remain in the intestinal lumen feeding on surrounding nutrients. About 10–20 % of the infections develop into amoebiasis which causes 70,000 deaths each year. Treatment failure among amoebiasis patients often raises the possibility of drug resistance (Ayala, 1990).

Metronidazole is the mainstay of therapy for invasive amebiasis. Tinidazole has been approved by the US Food and Drug Administration (FDA) for intestinal or extra-intestinal amebiasis. Other nitroimidazoles with longer half-lives (ie, secnidazole and ornidazole) are currently unavailable in the United States. Nitroimidazole therapy leads to clinical response in approximately 90% of patients with mild-to-moderate amebic colitis.

The objective of the study is to determine the therapeutic efficacy of combination of anti-amoebic drug against clinical isolates of *E. histolytica*. The clinical isolates of *Entamoeba histolytica* were treated with metronidazole, ornidazole, metronidazole+ornidazole, secnidazole, metronidazole+secnidazole, tinidazole, metronidazole+tinidazole at different concentrations. The concentrations of all anti-amoebic drugs were 12, 6, 3 & 1.5 mg/ml in this present experiment.

It has been shown from a study that the Metronidazole was superior to that of dehydroemetine but was not significantly different among ornidazole, metronidazole and tinidazole (Chintana et al, 1986). In our present study, combination of metronidazole and ornidazole (1.5 mg/ml) inhibit the growth of *E histolytica* and it is significantly different when compared with the control ( $p < 0.05$ ). Combination of tinidazole and metronidazole at the concentration of 6

and 12mg/ml is statistically significant ( $p < 0.05$ ) to inhibit the growth of *E. histolytica* when compared with the control. At the concentration of 3 mg/ml, only tinidazole is significantly different when compared with the control.

Metronidazole is currently the drug of choice for treating invasive amoebiasis in adults and children. Unfortunately metronidazole resistance for the treatment of amoebic dysentery is an increasing concern (Jarrad, 2016). Therefore, it is now an important concern to develop other treatment options to combat parasitic infection caused by *E. histolytica* (Wassmann, 1999). To reduce the side effects and the risk of developing resistance, combination regimens of antiamoebic drugs might have advantages.

Metronidazole, the current recommended first-line drug for treating amoebic colitis, is a tissue amoebicide predominantly but with some activity against cysts in the bowel lumen. Among the other nitroimidazole drugs, only tinidazole had a sufficient number of trials to be able to draw any meaningful conclusions in the pooled results. The pooled results show that tinidazole demonstrated greater resolution of clinical symptoms, but there was inconclusive evidence of its advantage over metronidazole in eradication of *E. histolytica* in the stools. The comparable parasitological response could be attributed to similar activities of drugs belonging to the nitroimidazole drug class. In one trial, the poor eradication of parasites with tinidazole was attributed to its greater absorption and higher blood and tissue concentrations, possibly resulting in inadequate levels in the bowel lumen (Pehrson 1984). Lower concentrations of tinidazole could also be explained by the suboptimal dosing interval used in some trials (Misra 1974; Joshi 1975; Mathur 1976; Pehrson 1984). Tinidazole is better given as a single dose than divided doses because of its longer half life of approximately 12 to 14 hours resulting in longer concentrations in the body (Gonzales, 2009).

In this present study metronidazole alone is complying with the results of the combination of metronidazole and ornidazole. Again metronidazole alone is complying with the results of the combination of metronidazole and tinidazole.



The no of viable counts are decreased when the concentrations of drugs are increased. The lowest number of viable count of *E. histolytica* is found when treated with the 12 mg/ml concentration of drugs. The highest count has been seen in the control group.

Study of Combination Regimens of Anti-Amoebic Drugs for the Treatment of Amoebic Dysentery Caused by *E. histolytica* is an innovative treatment option against amoebiasis. This study may help to make awareness of both physicians and consumers to establish new combination drug.

### **3.5 Conclusion**

Amoebiasis is a parasitic infection caused by the *Entamoeba histolytica*. Amoebiasis is the third leading parasitic cause of morbidity and mortality due to parasitic disease in human after malaria and schistosomiasis. On a global basis, amoebiasis affects approximately 50 million people each year resulting in 100,000 deaths. Metronidazole, Ornidazole, Secnidazole and Tinidazole are anti-amoebic agents. These are used for the treatment of amoebiasis. This study has been carried out to understand the effectiveness of different combination of anti-amoebic drugs against the *E. histolytica*. In this study *In-vitro* sensitivity has been demonstrated with the combination regimens of anti-amoebic drugs against clinical isolates of *E. histolytica*. However, there is insufficient evidence to draw conclusions regarding efficacy of combination drugs. Combination drug therapy may be more effective when compared with the Metronidazole alone.

## Reference

- Ayala P, Samuelson D, Wirth and Orozco E, 1990. *Entamoeba histolytica*: Physiology of multidrug resistance. *Exp. Parasitol*; 71: 169-175.
- Beeching, Nick, Gill, Geoff, 2014. "19" Lecture Notes: Tropical Medicine. *John Wiley & Sons*; 177-182.
- Chintana T, Sucharit P, Mahakittikun V, Siripanth C, Suphadtanaphongs W, 1986. *In vitro* studies on the sensitivity of local *Entamoeba histolytica* and other *Entamoeba*. *Southeast Asian J Trop Med Public Health*; 17(4):591-4.
- Devendra B, Rakesh S, Yogesh C, Ramesh CM and Nancy M, 2004. *In vitro* activity of antiamebic drugs against clinical isolates of *Entamoeba histolytica* and *Entamoeba dispar*, *Annals of Clinical Microbiology and Antimicrobials*; 3:27
- Farrar J, Hotez P, Junghanss T, Kang G, Lalloo D, White NJ, 2013. Manson's Tropical Diseases. *Elsevier Health Sciences*. 664-671.
- Fotedar R, Stark D, Beebe N, Marriott D, Ellis J and Harkness J, 2007. Laboratory Diagnostic Techniques for *Entamoeba* Species. *Clinical Microbiology reviews*; 20(3): 511-532.
- Gayatri V, Nair, Easwaran P, 2014. Noninvasive intestinal amebiasis: *Entamoeba histolytica* colonization without invasion. *Variyam Curr Opin Infect Dis.*; 27(5): 465-469.
- Gale Encyclopedia of Medicine, 2008. Amebiasis. *thefreedictionary.com*; 19 Jun. 2016 <<http://medical-dictionary.thefreedictionary.com/amebiasis>>.
- Gurvinder R, 2014. Pathogenic Free-living Amoeba. *Patient*; 1-6.
- Gonzales MLM, Dans LF, Martinez EG, 2009. Antiamebic drugs for treating amoebic colitis (Review). *Cochrane Database of Systematic Reviews*; Issue 2. Art. No.: CD006085.

Hardman JG, Limbird LE, Gilman AG, 2001. Goodman and Gilman's The Pharmacological Basis of Therapeutics. 10th ed. New York, NY: McGraw-Hill; 1106

Hoque MI, Uddin MS, Sarker AR, Uddin MK, 2014. Common presentation of amebic liver abscess - a study in a tertiary care hospital in Bangladesh. *Mymensing Med. J.*; 23(4):724-9.

Haque R, Mondal D, Duggal P, 2006. *Entamoeba histolytica* Infection in Children and Protection from Subsequent Amebiasis . *Infection and Immunity*; 74(2):904-909.

Jarrad AM, Debnath A, Miyamoto Y, Hansford KA, Pelingon R, Butler MS, Bains T, Karoli T, Blaskovich MA, Eckmann L, Cooper MA, 2016. Nitroimidazolecarboxamides as antiparasitic agents targeting *Giardia lamblia*, *Entamoeba histolytica* and *Trichomonas vaginalis*. *Eur J Med Chem.*; 120: 353-362.

Kafadar I, Moustafa F, Yalçın K, Kılıç BA, 2013. A rare adverse effect of metronidazole: nervous system symptoms. *PediatrEmerg Care*; 29 (6): 751-2.

Looke DFM, 1986. Metronidazole and tinidazole compared. *Australian Prescriber*; 10 (2):35-7.

Mathur SN, Itigi A, Rao PD, Krishnaveni, Rai V, 1976. Evaluation of tinidazole in treatment of amoebiasis. *Indian Medical Gazette.*; 11:361-4.

Marie C, Petri WJ, 2013. Amoebic dysentery. *BMJ ClinEvid*; 0918

McEvoy GK, 2006. American Hospital Formulary Service. AHFS Drug Information. *American Society of Health-System Pharmacists*; 892

Misra NP, Laiq SM, 1974. Comparative trial of tinidazole and metronidazole in intestinal amebiasis. *Current Therapeutic Research*; 16(12):1255-63.

- Monro AM, 1974. Blood levels of chemotherapeutic drugs and the pharmacokinetics of tinidazole and metronidazole. *Current Medical Research and Opinion*; 2(3):130-6.
- National Center for Biotechnology Information. *PubChem Compound Database*; CID=4173, <https://pubchem.ncbi.nlm.nih.gov/compound/4173> (accessed Jan. 23, 2016).
- Paul J, Srivastava S, Bhattacharya S, 2007. Molecular methods for diagnosis of *Entamoeba histolytica* in a clinical setting: An overview. *Experimental parasitology*; 116(1):35-43.
- Pehrson P, Bengtsson E, 1984. Treatment of non-invasive amoebiasis - a comparison between tinidazole and metronidazole. *Annals of Tropical Medicine and Parasitology*; 78(5):505-8.
- Petri W, Tanyuskel M, 2003. Laboratory Diagnosis of Amebiasis. *Clinical Microbiology reviews*; 16(4): 713-729.
- Qvarnstrom Y, da Silva AJ, Schuster FL, 2009. Molecular confirmation of *Sappinia pedata* as a causative agent of amoebic encephalitis. *J Infect Dis.*; 199(8):1139-42.
- Saritha P, 2015. Parasite *Entamoeba Histolytica* : Life Cycle, Mode of Infection and Treatment. *Your Article Library*; 1.
- Showler, Adrienne J and Andrea KB, 2013. *Entamoeba histolytica*. *Canadian Medical Association Journal*; 1064.
- Smith RF, Bocharadt, 2007. An evaluation of an InPouch TV culture method for diagnosing *Trichomonas vaginalis* infection. *Genitourin. Med.*; 67:149-152.
- Sodeman WAJ, 1996. Intestinal Protozoa: Amebas. In: Baron S, editor. *Medical Microbiology*. 4th edition. *University of Texas Medical Branch at Galveston*; Chapter 79.
- Thomson, 2006. Drug Information for the Health Care Professional. *Greenwood Village, CO*; 1:2831

Trabelsi H, Dendana F, Sellami A, 2012. Pathogenic free-living amoebae: epidemiology and clinical review. *Pathol Biol (Paris)*.; 60(6):399-405.

UXL Encyclopedia of Science, 2002. Amoeba. *Encyclopedia.com*; 19 Jun. 2016 <<http://www.encyclopedia.com>>.

Vinod K D, 2015. Amebiasis.Medscape

Visvesvara GS, Moura H, Schuster FL, 2007. Pathogenic and opportunistic free-living amoebae: *Acanthamoeba* spp., *Balamuthia mandrillaris*, *Naegleria fowleri*, and *Sappinia diploidea*. *FEMS Immunol Med Microbiol.*; 50(1):1-26.

Visvesvara GS, 2013. Infections with free-living amebae. *Handb Clin Neurol.*; 114:153-68.

Wassmann C, Hellberg A, Tannich E, Bruchhaus I, 1999. Metronidazole resistance in the protozoan parasite *Entamoeba histolytica* is associated with increased expression of iron-containing superoxide dismutase and peroxiredoxin and decreased expression of ferredoxin 1 and flavin reductase. *J. Biol. Chem.*; 274:26051-26056.

Weedall GD, Clark CG, Koldkjaer P, Kay S, Bruchhaus I, Tannich E, Paterson S, Hall N, 2013. Genomic diversity of the human intestinal parasite *Entamoeba histolytica*. *Genome biology*; 13(5): 156.

Weedall GD, Hall N, 2011. Evolutionary genomics of *Entamoeba*. *Research in Microbiology*; 162(6-2):637-645.